

# Early Experience with Biodegradable Fixation of Pediatric Mandibular Fractures

Ahmed Salah Mazeed, MSc<sup>1</sup> Mohammed Abdel-Raheem Shoeib, MD<sup>1</sup>  
Samia Mohammed Ahmed Saied, MD<sup>1</sup> Ahmed Elsherbiny, MD<sup>1</sup>

<sup>1</sup> Department of Plastic and Reconstructive Surgery, Sohag University Hospital, Sohag, Egypt

Address for correspondence Ahmed Salah Mazeed, MSc, Department of Plastic and Reconstructive Surgery, Sohag University Hospital, Naser City, Sohag 82524, Egypt (e-mail: salah\_doctor@yahoo.com).

Craniomaxillofac Trauma Reconstruction 2015;8:205–210

## Abstract

This clinical study aims to evaluate the stability and efficiency of biodegradable self-reinforced poly-L/DL-lactide (SR-PLDLA) plates and screws for fixation of pediatric mandibular fractures. The study included 12 patients (3–12 years old) with 14 mandibular fractures. They were treated by open reduction and internal fixation by SR-PLDLA plates and screws. Maxillomandibular fixation was maintained for 1 week postoperatively. Clinical follow-up was performed at 1 week, 6 weeks, 3 months, and 12 months postoperatively. Radiographs were done at 1 week, 3 months, and 12 months postoperatively to observe any displacement and fracture healing. All fractures healed both clinically and radiologically. No serious complications were reported in the patients. Normal occlusion was achieved in all cases. Biodegradable osteofixation of mandibular fractures offers a valuable clinical solution for pediatric patients getting the benefit of avoiding secondary surgery to remove plates, decreasing the hospital stay, further painful procedures, and psychological impact.

## Keywords

- mandibular fracture
- biodegradable fixation
- SR-PLDLA

The mandible is a common site of maxillofacial fractures because of its position and prominence. The overall goals of treatment of pediatric mandibular fractures are to restore proper function (mastication and articular movements). This is achieved by reduction of fracture, proper fixation to ensure union of the fractured segments, and the reestablishment of the patient's normal occlusion.<sup>1</sup>

Titanium plates and screws are routinely used for osteofixation of maxillofacial fractures including mandibular fractures. However, titanium devices have several potential problems which could necessitate removal.<sup>2</sup> These include allergic hypersensitivity, thermal conductivity, unacceptable palpability, and infection around the hardware.<sup>3</sup> Pain and irritation also were reported causes of plate removal.<sup>4</sup>

In a retrospective review of 279 patients with isolated mandibular fractures fixed with titanium miniplates, Tuovinen et al reported a plate removal rate of 11.5%.<sup>5</sup> Matthew and Frame interviewed 23 consultant oral and

maxillofacial surgeons and concluded that the incidence of plate removal ranged from 5 to 40%, with a mean removal rate of 13%.<sup>6</sup>

In children, metal plates should be removed after bone healing to avoid growth disturbances. This is also associated with additional hospitalization time, relatively high morbidity, and an increased burden on the health system.<sup>7</sup>

Bioresorbable plates have become an established alternative to metal fixation in reconstructive, trauma, and orthognathic craniomaxillofacial surgery.<sup>8</sup> Currently, there are different materials of biodegradable devices in the market. Also, different manufacturing technologies could affect the physical character of the device. The main advantage of the use of the biodegradable devices in children is the avoidance of a second surgery to remove the metal plates.

We are reporting our early experience with one type of biodegradable fixation system (self-reinforced poly-L/DL-lactide [SR-PLDLA]) in pediatric patients younger 12 years.

## received

March 25, 2014

## accepted after revision

May 27, 2014

## published online

December 23, 2014

Copyright © 2015 by Thieme Medical Publishers, Inc., 333 Seventh Avenue, New York, NY 10001, USA.  
Tel: +1(212) 584-4662.

DOI <http://dx.doi.org/10.1055/s-0034-1393735>.  
ISSN 1943-3875.

Stability and efficiency of biodegradable plates and screws for fixation of pediatric mandibular fractures were assessed.

## Patients and Methods

This is a prospective study performed in the period from October 2011 to February 2013. It included pediatric patients (12 years or younger) presented to the emergency department in a tertiary referral university hospital with mandibular fractures amenable for open reduction and internal fixation with miniplates and screws and who express the ability to return for follow-up.

Patient evaluation included the demographic data and the history related to the mandibular trauma as the cause and time of injury. History also included dental hygiene, tooth disease, preinjury malocclusion, and any temporomandibular joint (TMJ) symptoms. History of any previous facial injuries or maxillofacial surgeries done was also included. Patients were examined for signs of mandibular fracture including swelling, ecchymosis, deformity, crepitus, gingival lacerations, missing teeth, stability of remaining teeth, malocclusion, and restrictions or deviations in opening, closing, or protrusion. Computed tomography (CT) radiographs were taken preoperatively. Fractures were classified according to the site and also according to displacement into undisplaced, slightly displaced (less than one cortical thickness overlap) and severely displaced (more than one cortical thickness overlap) fractures. A penicillin-based antibiotic (amoxicillin/clavulanic acid, 50 mg/kg/d divided in two doses) was administered once the patient is seen and for 1 week postoperatively.

## The Operative Procedure

The procedures were done under general anesthesia and nasal intubation. Fracture exposure was done through either transbuccal approach (in symphyseal or anterior body fractures) or submandibular approach (in angle fractures). Maxillomandibular fixation (MMF) was done to restore the patient's occlusion by one of the following methods: Erich arch bars, Ernst ligatures, or circummandibular wiring and maxillary screws according to the state of dentition. The fracture was reduced and osteosynthesis was achieved with 2.0 or 2.5 mm biodegradable self-reinforced poly (L/DL) lactic acid plates and screws (INION, Tampere, Finland) (►Fig. 1). The plates were adapted to the fracture site by bending. The screw holes were drilled and tapped, then screws were applied (►Fig. 2). When the fractures were at the symphyseal region or severely displaced, two plates were used; otherwise one plate was used. Monocortical screws were used in all the cases. After surgery, MMF was maintained for 1 week postoperatively.

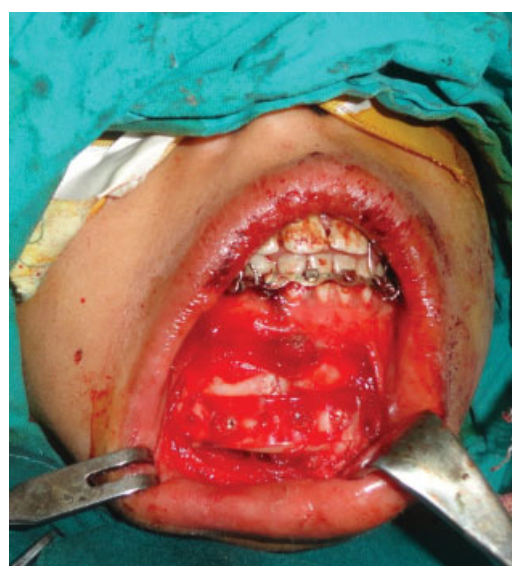The follow-up appointments were at 1 week, 6 weeks, 3 months, and 12 months postoperatively with the assessment of any wound complications as infection, dehiscence, and fistula formation, stability, displacement, malocclusion, mouth opening limitation, TMJ ankylosis, and disturbances of sensation. Radiographic follow-up by CT scan was done to observe any displacement and fracture healing at 1 week, 3 months, and 12 months postoperatively.



**Fig. 1** INION (self-reinforced poly-L/DL-lactide) biodegradable 2.5-mm plate and screw used in this study.

## Results

In the period from October 2011 to February 2013, 12 children with mandibular fractures (►Table 1) were managed using the biodegradable plating system. The average age was 7.16 years (range from 3 to 12 years), nine males and three females giving male-to-female ratio (3:1). The time interval between the occurrence of trauma and surgical intervention was variable with an average of 2 days (range, 0–5 days). The etiology of the fractures was road traffic accident in 10 patients (83.3%) and falls in 2 patients (16.7%). These patients had 14 fractures (10 single and 2 double): 2 symphyseal, 6 parasymphyseal, 3 bodies, and 3 angle fractures. Fractures were undisplaced in three cases, slightly displaced in four cases, and severely displaced in seven cases. The mean hospital stay was 4 days. The number of plates used per patient ranged from one to two, and the number of screws from four to eight.



**Fig. 2** Intraoperative photograph showing right parasymphyseal fracture of the mandible (patient no. 2) fixed with 2.5-mm self-reinforced poly-L/DL-lactide plate and screws through transbuccal approach.

**Table 1** Patients data

Patient	Age (y)	Sex	Etiology	Fracture site	Fixation device	Number of implants	Complications
1	9	F	Fall	Symphysis	Plates	2	None
					screws	8	
2	12	M	RTA	Rt. Parasymphysis Lt. angle	Plates	2	None
					Screws	8	
3	7	F	RTA	Symphysis	Plates	2	None
					Screws	8	
4	5	M	RTA	Lt. body	Plates	1	None
					Screws	4	
5	10	M	RTA	Rt. Parasymphysis	Plates	1	None
					Screws	4	
6	5	M	RTA	Lt. Parasymphysis	Plates	1	Wound dehiscence → healed in 1 mo
					Screws	4	
7	11	M	RTA	Rt. body	Plates	1	None
					Screws	4	
8	6	M	Fall	Rt. Parasymphysis	Plates	1	Wound dehiscence → 1 cm exposed bone after 6 wk
					Screws	5	
9	3	F	RTA	Lt. body	Plates	1	None
					Screws	4	
10	8	M	RTA	Lt. Parasymphysis Rt. angle	Plates	2	None
					Screws	8	
11	4	M	RTA	Lt. angle	Plates	2	None
					Screws	8	
12	6	M	RTA	Lt. Parasymphysis	Plates	1	None
					screws	4	

Abbreviations: F, female; Lt., left; M, male; Rt., right; RTA, road traffic accident.

Healing of soft tissue was good in all patients except two patients had buccal wound dehiscence after 1 week. After 6 weeks, only one patient had dehiscence with 1 cm exposed bone which was managed conservatively by mouth wash and antibiotics. This patient had a bad oral hygiene and complete healing was reported at the 3 months follow-up visit. The radiographic follow-up of all the patients showed good bone healing without any signs of instability of the fixation (→ **Figs. 3 and 4**). Other complications such as mouth opening limitation and TMJ ankylosis were not identified. No disturbances of sensation were observed. During the follow-up, no evidence of tissue intolerance or malocclusion was noticed. Normal occlusion could be restored in all the cases (→ **Fig. 5**).

In all the cases, the biodegradable fixation system provided enough stability to enable bone healing both clinically and radiologically. The clinical outcome was excellent in 11 of the 12 cases (91.6%). The complication reported did not affect bone healing.

## Discussion

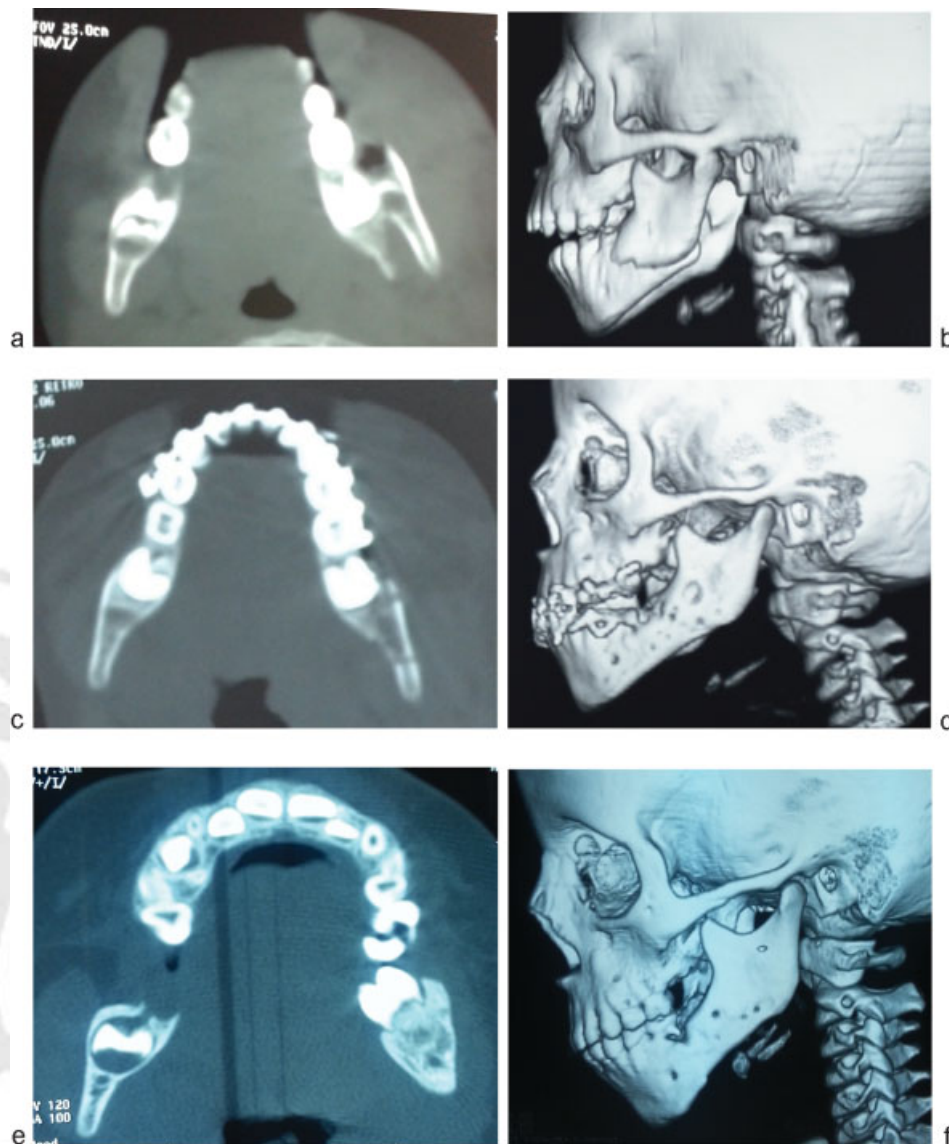
Beside the average, 13% removal rate with the use of titanium plates due to complications, the metal plates in children

should be removed routinely to avoid the possibility of growth restriction. The use of biodegradable materials provides children the advantage to avoid undergoing a second surgery to remove the metal plates.

Many biodegradable materials have been proved to be reliable in numerous studies such as polydioxanone, polyglycolic acid (PGA), poly-L-lactic acid (PLLA), poly-L/D-lactic acid (PLDLA), and their copolymers.<sup>7</sup>

Several studies reported the use of biodegradable plates and screws for craniomaxillofacial osteosynthesis. Self-reinforced polylactide materials (lag screws) were formerly used for fixation of sagittal split osteotomies of the mandible with good results.<sup>9</sup> Turvey et al<sup>10</sup> used SR-P(L/DL)LA plates and screws for fixation of 336 osteotomies of the maxilla and mandible in 130 orthognathic patients, concluding the efficiency of this material. The material showed enough initial strength to ensure stability of bone segments. At 15 months, the drill holes were filled with bone. Resorption of the material was complete by 2 to 3 years. Ylikontiola et al<sup>11</sup> used SR-PLDLA plates for the fixation of anterior mandibular fractures in 10 patients. The patients were followed for 3 to 6 months with good bone and soft





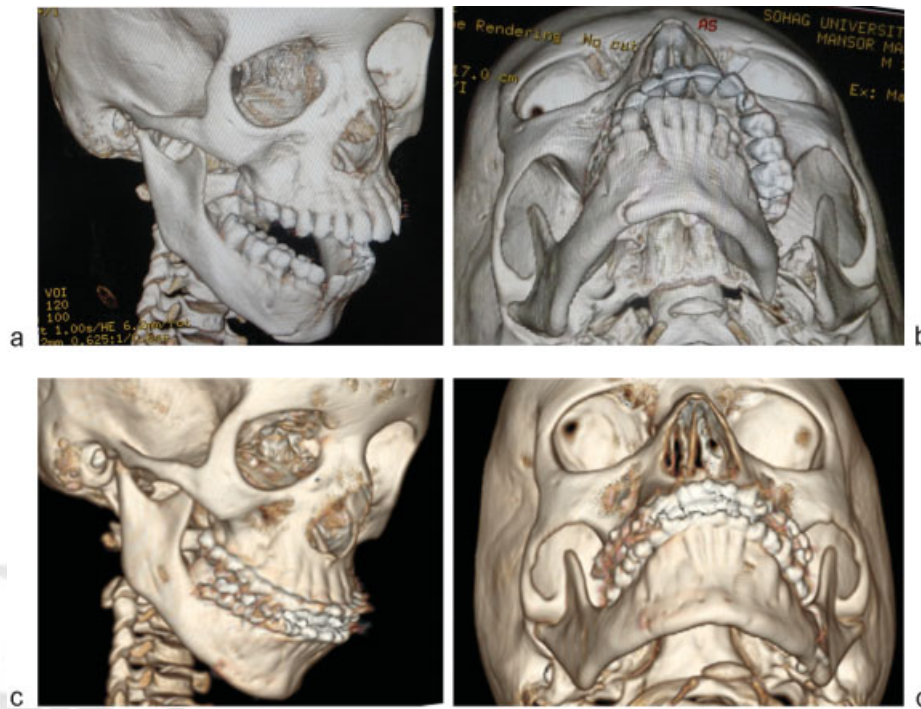**Fig. 3** A 4-year-old boy with left angle fracture of the mandible (patient no.11): (a) Axial computed tomography (CT) preoperative. (b) Three-dimensional (3D) CT preoperative. (c) Axial CT 1 week postoperative. (d) 3D CT 1 week postoperative. (e) Axial CT 1 year postoperative. (f) 3D CT 1 year postoperative. The plates are radiolucent and not visible. The fracture is healed completely. Some screw holes are still visible.

tissue healing and only a minor complication was reported in one patient. Leonhardt et al<sup>8</sup> also used SR-PLDLA (INION) plates for the fixation of mandibular fractures in 30 patients with heterogeneous age group with a mean follow-up period of 6 months. All the fractures healed both clinically and radiologically. All patients had perfect occlusions. No serious complications were reported in any of these studies and long-term stability was comparable to clinical reports on metallic devices.

In this study, we used self-reinforced material. The self-reinforcing technique enables the formation of small devices of ultra-high strength and bending tolerability. In this technique, a composite structure is made of a polymeric matrix reinforced with oriented reinforcing units. These units are in the form of fibrils or fibers arranged in the orientation of the axis and have the same chemical structure as the matrix itself.<sup>12</sup>

Earlier, it was not possible to apply bioresorbable materials in mandibular fractures due to their lower strength than the metal systems. The self-reinforcement technique improved the biomechanical characteristics of plates and screws and increased their strength.<sup>7</sup> In spite of the smaller size of these plates and screws compared with nonreinforced devices; they show high bending strength due to the self-reinforcement technology.<sup>11</sup> SR plates of the copolymer poly (L/DL) lactide are stronger than other commercially available biodegradable plates.<sup>10</sup> These self-reinforced biodegradable plates and screws can give adequate strength and stability for fixation of bone even in high-load areas such as the mandible.<sup>13</sup> Only the Inion plates are approved by the US Food and Drug Administration (FDA) for fixation of mandibular fractures with an appropriate period of MMF.<sup>14</sup>

The data presented show that the biodegradable INION system gives sufficient stability to allow bone healing. All



**Fig. 4** A 12-year-old boy with right parasymphyseal and left angle fracture of the mandible (patient no. 2). (a, b) Three-dimensional computed tomography (CT) preoperative. (c, d) 3D CT 1 week postoperative. The plates are radiolucent and not visible. Screw holes are visible.

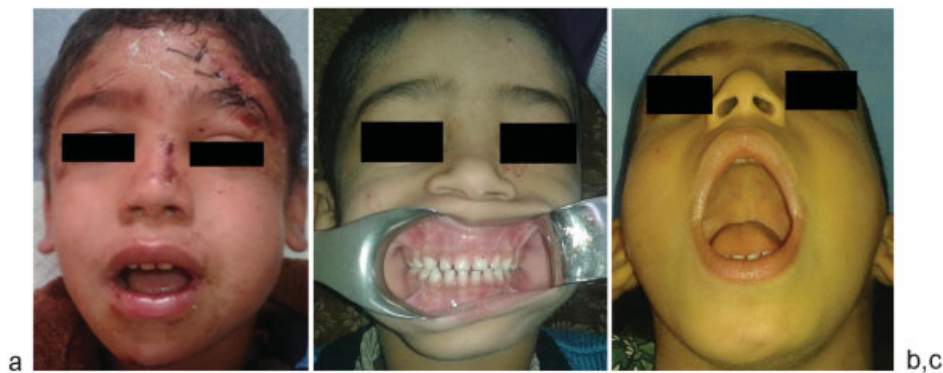fractures in this series healed successfully. As the PLDLA materials gain their final stability after 3 days in place; to reach a biomechanical rigidity similar to that of titanium plates,<sup>15</sup> we kept the MMF for a period of 1 week postoperative to prevent early instability. The FDA recommends not using the biodegradable plates in the mandible without an appropriate period of MMF.<sup>16</sup>

In this series, two cases developed buccal wound dehiscence (2/12) which did not affect bone healing. This incidence is comparable to the incidence reported in other studies.<sup>17</sup> Adequate soft tissue coverage prevents problems with healing and plate exposure. If implant exposure occur, the exposed part can be excised after fracture healing, which takes 6 to 8 weeks. On the contrary, exposure of titanium plates

represents a more problematic situation which can be managed conservatively or may require removal of the whole plate and screws in some cases.<sup>18</sup>

The copolymer PLDLA has a resorption time of 2 to 3 years. The degradation of polylactic acid involves hydrolytic enzymes.<sup>19</sup> There is a transient foreign body reaction which is responsible for the postoperative swelling. However, these foreign body reactions have a lower incidence and are rarely clinically manifested with SR devices in comparison with the ordinary PGA or PLLA.<sup>12</sup>

The blunt tips of the biodegradable screws and their eventual degradation reduce the harm on the developing teeth particularly in young children in the primary and mixed dentition periods. Another advantage is that the



**Fig. 5** A 5-year-old boy with left body fracture of the mandible (patient no. 4): (a) the patient at time of presentation 1 day after trauma. (b) 1 year postoperative photograph showing normal occlusion. (c) 1 year postoperative photograph showing full range of mouth opening.

biodegradable materials are radiolucent and do not interfere with imaging techniques.

The advantages of biodegradable plates avoiding the burden of removing the titanium plates (cost, time, further painful procedure for plate removal, much scar tissue formation) outweigh its disadvantages (cost and more difficult operative technique).

## Conclusion

Biodegradable SR-PLDLA plates and screws can give the initial strength needed for fixation of mandibular fractures followed by degradation and elimination from the body. The use of biodegradable osteofixation devices avoids secondary surgery to remove the plates and therefore reduce the overall cost. This also avoids the possible allergic reactions, cold sensitivity, pain, irritation, infection, and palpability of the metal plate. This is also associated with decreased physical and psychological trauma to the child. However, further clinical studies are needed to assess the long-term results of mandibular fractures treatment with biodegradable systems.

## References

- 1 Chacon GE, Larsen PE. Principles of management of mandibular fractures. In: Miloro M, Ghali GE, Larsen PE, Waite PD, eds. *Peterson's Principles of Oral and Maxillofacial Surgery*. Hamilton, Ontario, Canada: BC Decker Inc, 2004:401–433
- 2 Schliephake H, Lehmann H, Kunz U, Schmelzeisen R. Ultrastructural findings in soft tissues adjacent to titanium plates used in jaw fracture treatment. *Int J Oral Maxillofac Surg* 1993;22(1):20–25
- 3 Iizuka T, Lindqvist C. Rigid internal fixation of mandibular fractures. An analysis of 270 fractures treated using the AO/ASIF method. *Int J Oral Maxillofac Surg* 1992;21(2):65–69
- 4 Mosbah MR, Oloyede D, Koppel DA, Moos KF, Stenhouse D. Miniplate removal in trauma and orthognathic surgery—a retrospective study. *Int J Oral Maxillofac Surg* 2003;32(2):148–151
- 5 Tuovinen V, Nørholt SE, Sindet-Pedersen S, Jensen J. A retrospective analysis of 279 patients with isolated mandibular fractures treated with titanium miniplates. *J Oral Maxillofac Surg* 1994; 52(9):931–935, discussion 935–936
- 6 Matthew IR, Frame JW. Policy of consultant oral and maxillofacial surgeons towards removal of miniplate components after jaw fracture fixation: pilot study. *Br J Oral Maxillofac Surg* 1999; 37(2):110–112
- 7 Yerit KC, Hainich S, Enislidis G, et al. Biodegradable fixation of mandibular fractures in children: stability and early results. *Oral Surg Oral Med Oral Pathol Oral Radiol Endod* 2005;100(1): 17–24
- 8 Leonhardt H, Demmrich A, Mueller A, Mai R, Loukota R, Eckelt U. INION compared with titanium osteosynthesis: a prospective investigation of the treatment of mandibular fractures. *Br J Oral Maxillofac Surg* 2008;46(8):631–634
- 9 Suuronen R, Laine P, Pohjonen T, Lindqvist C. Sagittal ramus osteotomies fixed with biodegradable screws: a preliminary report. *J Oral Maxillofac Surg* 1994;52(7):715–720, discussion 720–721
- 10 Turvey TA, Bell RB, Tejera TJ, Proffit WR. The use of self-reinforced biodegradable bone plates and screws in orthognathic surgery. *J Oral Maxillofac Surg* 2002;60(1):59–65
- 11 Ylikontiola L, Sundqvist K, Sándor GK, Törmälä P, Ashammakhi N. Self-reinforced bioresorbable poly-L/DL-lactide [SR-P(L/DL)LA] 70/30 miniplates and miniscrews are reliable for fixation of anterior mandibular fractures: a pilot study. *Oral Surg Oral Med Oral Pathol Oral Radiol Endod* 2004;97(3):312–317
- 12 Törmälä P. Biodegradable self-reinforced composite materials; manufacturing structure and mechanical properties. *Clin Mater* 1992;10(1-2):29–34
- 13 Kim YK, Kim SG. Treatment of mandible fractures using bioabsorbable plates. *Plast Reconstr Surg* 2002;110(1):25–31, discussion 32–33
- 14 Vázquez-Morales DE, Dyalram-Silverberg D, Lazow SK, Berger JR. Treatment of mandible fractures using resorbable plates with a mean of 3 weeks maxillomandibular fixation: a prospective study. *Oral Surg Oral Med Oral Pathol Oral Radiol* 2013;115(1):25–28
- 15 Wood GD. Inion biodegradable plates: the first century. *Br J Oral Maxillofac Surg* 2006;44(1):38–41
- 16 FDA (US Food and Drug Administration). Center for Devices and Radiological Health (CDRH), Office of Device Evaluation, 2001. Available at: [http://www.accessdata.fda.gov/cdrh\\_docs/pdf/k010352.pdf](http://www.accessdata.fda.gov/cdrh_docs/pdf/k010352.pdf). Accessed on December 3, 2014
- 17 Eppley BL, Sadove AM, Havlik RJ. Resorbable plate fixation in pediatric craniofacial surgery. *Plast Reconstr Surg* 1997;100(1): 1–7, discussion 8–13
- 18 Ferretti C. A prospective trial of poly-L-lactic/polyglycolic acid copolymer plates and screws for internal fixation of mandibular fractures. *Int J Oral Maxillofac Surg* 2008;37(3):242–248
- 19 Hollinger JO. Preliminary report on the osteogenic potential of a biodegradable copolymer of polylactide (PLA) and polyglycolide (PGA). *J Biomed Mater Res* 1983;17(1):71–82